

# Anaesthetic management for endovascular treatment of unruptured intracranial aneurysms

Zbigniew Karwacki<sup>1</sup>, Małgorzata Witkowska<sup>1</sup>, Seweryn Niewiadomski<sup>1</sup>, Andrzej Wiatr<sup>1</sup>, Paweł Bukowski<sup>1</sup>, Jolanta Wierzchowska<sup>1</sup>, Adam Zapaśnik<sup>2</sup>

<sup>1</sup>Department of Neuroanaesthesiology, Medical University of Gdańsk, Poland

<sup>2</sup>Department of Neuroradiology, Medical University of Gdańsk, Poland

## Abstract

**Background.** Endovascular techniques for treatment of intracranial aneurysms are increasingly commonly applied. In general, the procedures are short, require general anaesthesia and complete immobilisation of patients. The aim of the present study was to assess the usefulness of general anaesthesia with propofol and laryngeal mask airway for endovascular management of intracranial aneurysms based on analysis of haemodynamic stability.

**Material and methods.** The study encompassed 26 patients undergoing endovascular treatment of intracranial aneurysms. The mean arterial pressure (MAP), heart rate (HR), bispectral index (BIS), end-tidal CO<sub>2</sub> (E<sub>T</sub>CO<sub>2</sub>) and haemoglobin saturation with oxygen (SpO<sub>2</sub>) were determined at eight measurement points: T<sub>1</sub> — before anaesthesia induction, T<sub>2</sub> — after induction, T<sub>3</sub> — after LMA insertion, T<sub>4</sub> — during arteriography, T<sub>5</sub> — during “coiling”, T<sub>6</sub> — at completion of propofol infusion, T<sub>7</sub> — before LMA removal, T<sub>8</sub> — after LMA removal.

**Results.** MAP and HR were found significantly reduced between T<sub>2</sub> and T<sub>1</sub>. To maintain BIS within the range of 40–60, the following propofol infusion rates (in mg kg b.w.<sup>-1</sup> h<sup>-1</sup>) were required: T<sub>2</sub> — 4.5 ± 0.3; T<sub>3</sub> — 4.6 ± 0.7; T<sub>4</sub> — 4.5 ± 0.8 and T<sub>5</sub> — 4.4 ± 0.6. E<sub>T</sub>CO<sub>2</sub> and SpO<sub>2</sub> were not demonstrated to be changed. The mean duration of anaesthesia and of recovery was 64.3 ± 21.8 and 8.9 ± 4.8 min., respectively.

**Conclusions.** General anaesthesia with propofol and LMA ensures suitable conditions for endovascular treatment of intracranial aneurysms.

**Key words:** general anaesthesia, intracranial aneurysm; general anaesthesia, interventional neuroradiology; anaesthetics, propofol; artificial airway, laryngeal mask airway

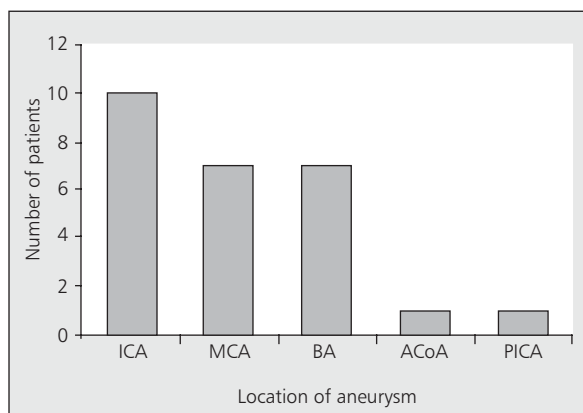
Anaesthesiology Intensive Therapy 2013, vol. 45, no 3, 145–148

In recent years, the use of endovascular treatment in CNS vascular diseases, including intracranial aneurysms (ICAs), has become increasingly widespread in interventional neuroradiology [1]. The endovascular treatment of “cold” ICAs is associated with an extremely low risk of complications and low mortality rates [2]. During the last decade, this method was recognised as an alternative to invasive treatment options [3]. At most centres worldwide, anaesthesiologists are responsible for the patient’s safety during such procedures [4]. The range of their responsibilities includes the provision of optimal conditions for neuroradiologists; monitoring of the patient’s status; and the institution of activities to reduce the consequences of complications, whenever present [5, 6].

The aim of the present study was to evaluate the usefulness of general anaesthesia with propofol and a laryngeal mask airway (LMA) for the endovascular treatment of unruptured ICAs, based on an analysis of cardiovascular stability.

## METHODS

The study protocol was approved by the local bioethics committee. The population consisted of 26 ASA I patients (22 females and four males) who had unruptured ICAs of grade I according to the World Federation of Neurological Surgeons’ scale and who were scheduled for endovascular treatment. The mean age of the patients was 54.2 ± 7.6 years, and the mean body weight was 75.4 ± 14.7 kg. The distribution of aneurysm locations in the study population is presented in Fig. 1.



**Figure 1.** Location of aneurysms in the study population (ICA — internal carotid artery, MCA — middle cerebral artery, BA — basilar artery, ACoA — anterior communicating artery, PICA — posterior inferior cerebellar artery)

Forty minutes before the procedure, the patients were premedicated with oral midazolam ( $0.3 \text{ mg kg b.w.}^{-1}$ ). Anaesthesia was induced with propofol ( $1.5 \text{ mg kg b.w.}^{-1}$ ) and fentanyl ( $2 \text{ } \mu\text{g kg b.w.}^{-1}$ ). The lungs were ventilated with 100% oxygen via a face mask. An LMA was inserted after the administration of vecuronium at a dose of  $0.1 \text{ mg kg b.w.}^{-1}$ . Anaesthesia was maintained by the continuous infusion of propofol at a rate enabling the maintenance of a BIS within the range of 40–60. During anaesthesia, the lungs were mechanically ventilated with a mixture of oxygen and air (1:1 ratio). The following parameters were continuously monitored: the bispectral index (BI), mean arterial pressure (MAP), heart rate (HR),  $E_T\text{CO}_2$  and percutaneous  $\text{SpO}_2$ .

The analysed parameters were determined at eight measurement points:  $T_1$  — before anaesthesia induction,  $T_2$  — after induction,  $T_3$  — after LMA insertion,  $T_4$  — during arteriography,  $T_5$  — during intravascular coil spring insertion,  $T_6$  — at the completion of propofol infusion,  $T_7$  — before LMA removal and  $T_8$  — after LMA removal.

During the procedure, Ringer's solution was continuously infused at a rate of  $5 \text{ mL kg b.w.}^{-1} \text{ h}^{-1}$ , and hourly

diuresis monitored. At the procedure onset, an i.v. bolus of heparin at  $100 \text{ u kg b.w.}^{-1}$  was administered, and a dose of 1000 units was repeated every hour.

Statistical analysis was performed using GraphPad InStat 3.10 for Windows (GraphPad Software Inc., USA). The data are presented as the mean  $\pm$  SD. The data distribution was assessed using the Kolmogorov-Smirnov test. Depending on the distribution type found, the Tukey-Kramer or Dunn test was used.  $P < 0.05$  was considered as statistically significant.

## RESULTS

The results are presented in Table 1. Significant changes in the BIS were observed between  $T_1$  and  $T_2$  and between  $T_6$  and  $T_7$ . Moreover, significant differences in the MAO and HR were noted between  $T_1$  and  $T_2$ . No differences in the  $E_T\text{CO}_2$ ,  $\text{SpO}_2$  and mean infusion rates of propofol were found (Table 1).

The mean durations of anaesthesia and recovery were  $64.3 \pm 21.8$  and  $8.9 \pm 4.8$  min, respectively.

## DISCUSSION

There are only few literature reports comparing sedation and general anaesthesia in interventional neuroradiology [4, 7, 8]. The occurrence of vasospasm and/or elevated intracranial pressure increases the risk of complications accompanying anaesthetic management aimed at protecting against aneurysm rupture by reducing the systemic pressure [7]. General anaesthesia is believed to have various advantages compared with sedation [4]. By ensuring the stillness of patients, this anaesthesia minimises the risk of accidental vessel puncture. Furthermore, the method secures higher haemodynamic stability and eliminates the hazard of impaired airway patency. Thanks to general anaesthesia, patients undergoing surgery are provided with comfort when complications develop or the procedure is prolonged [4–6]. The most important disadvantages of general anaesthesia include a lack of possible neurological assessment during the procedure and circulatory sequelae of laryngoscopy, intubation and extubation, leading to increases in intracranial pressure [7].

**Table 1.** Monitored parameters (mean  $\pm$  SD)

Parameter	Measurement point							
	$T_1$	$T_2$	$T_3$	$T_4$	$T_5$	$T_6$	$T_7$	$T_8$
MAP (mm Hg)	107.1 $\pm$ 19.5	84.2 $\pm$ 14.9*	85.5 $\pm$ 17.2	82.8 $\pm$ 16.9	82.8 $\pm$ 14.6	89.3 $\pm$ 18.7	102.9 $\pm$ 22.4	108.2 $\pm$ 26.4
HR ( $\text{min}^{-1}$ )	85.8 $\pm$ 16.5	73.1 $\pm$ 15.0*	71.1 $\pm$ 15.6	67.4 $\pm$ 14.0	66.3 $\pm$ 13.7	70.9 $\pm$ 13.6	79.3 $\pm$ 13.4	80.6 $\pm$ 13.6
$\text{SpO}_2$ (%)	97.2 $\pm$ 1.1	98.9 $\pm$ 0.7	98.7 $\pm$ 0.8	98.8 $\pm$ 0.9	99.0 $\pm$ 0.3	99.0 $\pm$ 0.7	99.0 $\pm$ 0.5	99.0 $\pm$ 0.7
$E_T\text{CO}_2$ (mm Hg)	–	–	36.7 $\pm$ 1.5	36.6 $\pm$ 1.9	36.0 $\pm$ 1.7	37.1 $\pm$ 2.1	36.9 $\pm$ 1.7	–
BIS	95.7 $\pm$ 4.1	37.5 $\pm$ 6.6*	48.2 $\pm$ 13.6*	5.6 $\pm$ 9.5	46.0 $\pm$ 8.2	54.6 $\pm$ 14.6	79.1 $\pm$ 9.0*	93.0 $\pm$ 6.4
Propofol infusion rate ( $\text{mg kg b.w.}^{-1} \text{ h}^{-1}$ )	–	4.5 $\pm$ 0.3	4.6 $\pm$ 0.7	4.5 $\pm$ 0.8	4.4 $\pm$ 0.6	–	–	–

\*significant difference ( $P < 0.05$ ) compared to the preceding value

The use of an LMA avoids the autonomic nervous system excitation induced by direct laryngoscopy, intubation and extubation [4, 8]. Our observations confirm that LMA use is the optimal method for securing the patency of the upper airways during anaesthesia for endovascular ICA repair. According to certain authors, the Cobra supralaryngeal device can be an alternative to an LMA [9, 10].

The key aim of anaesthetic management during intubation and anaesthesia maintenance in patients with ICAs is to maintain the transmural pressure gradient of the aneurysm sac at a constant level [5, 7, 8]. The risk of aneurysm rupture during endovascular treatment is estimated to be 2.5% [11], and 1% of cases are fatal. General anaesthesia with propofol or sevoflurane ensures rapid intubation without haemodynamic disturbances; fully controlled anaesthesia depth; and gentle, short-lasting recovery [4, 5]. The superiority of propofol over sevoflurane results from the fact that at concentrations exceeding 2 MAC, the latter anaesthetic increases the cerebral blood flow and CO<sub>2</sub> reactivity of cerebral vessels [7]. Moreover, the neuroprotective properties of propofol are of importance [13]. Our observations indicate that the combination of an intravenous hypnotic, an opioid and a non-depolarising relaxant prevents the increases in arterial pressure caused by LMA insertion.

During angiography and the placement of coil springs in the aneurysm sac, the extent of stimulation is markedly lower than during the induction of anaesthesia. The continuous infusion of propofol used in our study was found to be sufficient to maintain a suitable level of anaesthesia. Moreover, a relatively short recovery time after the use of propofol infusion enables an immediate evaluation of the patient's neurological status. In neurologically compromised and haemodynamically unstable patients, combining an infusion of propofol, remifentanyl or sufentanil at a low dose with a supply of sevoflurane is recommended [7].

The clinical symptoms of aneurysm rupture in anaesthetised patients result from a sudden increase in intracranial pressure [7]. Hypertension accompanied by bradycardia can be interpreted as a consequence of an insufficient depth of anaesthesia. In contrast, reflex hypotension can cause hypoperfusion, leading to ischaemic injuries. Therefore, standard monitoring during endovascular procedures involves ECG, SpO<sub>2</sub>, E<sub>T</sub>CO<sub>2</sub> and arterial pressure measurements, and particularly mean pressure value measurements [4, 6].

The current guidelines advocate the use of artificial lung ventilation, enabling the maintenance of normocapnia and proper oxygenation. This procedure limits the incidence of cerebral blood flow abnormalities and intravascular catheter-related increases in intracranial pressure [7]. Hypoventilation-induced cerebral vasodilation can impair the quality of cerebral vessel pictures on the monitor [8].

Thanks to dynamic advances in digital technologies and a better understanding of CNS electrophysiology, BIS monitoring could be introduced. The BIS is an integrated numerical value ranging from 0-100 that reflects the correlation between electroencephalographic and awareness changes [14]. A BIS maintained within the range of 40–60 ensures a deep depression of awareness, carrying the risk of awareness' return in anaesthetised patients [15]. Our observations fully confirm the usefulness of BIS monitoring during the endovascular repair of ICAs, especially given that a significant correlation was demonstrated between the BIS value and hypnotic concentration [15, 16]. It is believed that the BIS allows the control of awareness [16]. Luginbühl and co-workers [17] observed that BIS monitoring during anaesthesia with propofol reduced the anaesthetic dose and shortened the period of recovery. Rapid, gentle recovery from anaesthesia enables an early assessment of the patient's neurological status and safe transport of the patient from the neuroradiological laboratory to the intensive care unit.

A certain limitation of our analysis should be taken into account, i.e., the analysis of anaesthetic management during the endovascular treatment of unruptured aneurysms in patients in good general condition. It would be interesting to perform similar studies in patients with clinical manifestations accompanying subarachnoid haemorrhage.

## CONCLUSION

General anaesthesia with propofol and an LMA provides good conditions for the endovascular treatment of ICAs.

## References:

1. Young WL, Pile-Spellman J: Anesthetic considerations for interventional neuroradiology. *Anesthesiology* 1994; 8: 427–452.
2. Standhard H, Boecher-Schwarz H, Gruber A, et al.: Endovascular treatment of unruptured intracranial aneurysms with Guglielmi detachable coils. Short- and long-term results of a single-centre series. *Stroke* 2008; 39: 899–904.
3. Roy D, Milot G, Raymond J. Endovascular treatment of unruptured aneurysms. *Stroke* 2001; 32: 1998–2004.
4. Varma MK, Price K, Jayakrishnan V, et al.: Anaesthetic consideration for interventional neuroradiology. *Br J Anaesth* 2007; 99: 75–85.
5. Levy DM, Nowicki RWA: Anaesthesia for treatment of cerebral aneurysms. *CPD Anaesthesia* 2002; 4: 106–114.
6. Lai YC, Manninen PH: Anesthesia for cerebral aneurysms: a comparison between interventional neuroradiology and surgery. *Can J Anaesth* 2001; 48: 391–395.
7. Proiebe H-J: Aneurysmal subarachnoid haemorrhage and the anaesthetist. *Br J Anaesth* 2007; 99: 102–118.
8. Lakhani S, Guhta A, Nahser HC: Anaesthesia for endovascular management of cerebral aneurysms. *Eur J Anaesthesiol* 2006; 23: 902–913.
9. Wrońska-Seweruk A, Nestorowicz A, Kowalczyk M: Classic laryngeal mask airway vs COBRA-PLA device for airway maintenance during minor urological procedures. *Anaesthesiol Intensive Ther* 2009; 41: 61–64.
10. Ratajczyk P, Malachowska B, Gaszyńska E, Gaszyński T: A randomised comparison between Cobra PLA and classic laryngeal mask airway and laryngeal tube during mechanical ventilation for general anaesthesia. *Anaesthesiol Intensive Ther* 2013; 45: 20–24.
11. Brilstra EH, Rinkel GJE, van der Graaf Y, et al.: Treatment of intracranial aneurysms by embolization with coils: a systemic review. *Stroke* 1999; 30: 470–476.

12. *Sluzewski M, Bosch JA, van Rooij WJ, et al.*: Rupture of intracranial aneurysms during treatment with Guglielmi detachable coils: incidence, outcome, and risk factors. *J Neurosurg* 2001; 94: 238–240.
13. *Tobias J.D.*: Propofol: effects on the central nervous system. *J Intensive Care Med* 2000; 15: 237–241.
14. *Hanss R, Bauer M, Bein B, et al.*: Bispectral index-controlled anaesthesia for electroconvulsive therapy. *Eur J Anaesthesiol* 2006; 23: 202–207.
15. *Anderson RE, Jakobsson JG.*: Cerebral state monitor, a new small handheld EEG monitor for determining depth of anaesthesia: a clinical comparison with the bispectral index during day surgery. *Eur J Anaesthesiol* 2006; 23: 208–212.
16. *Johansen JW, Sebel PS.*: Development and clinical application of electroencephalographic bispectrum monitoring. *Anesthesiology* 2000; 93: 1336–1344.
17. *Luginbühl M, Wüthrich S, Petersen-Felix S, et al.*: Different benefit of bispectral index (BISTM) in desflurane and propofol anaesthesia. *Acta Anaesthesiol Scand* 2003; 47: 166–173.

**Corresponding author:**

*Prof. Zbigniew Karwacki, MD, PhD*  
*Zakład Neuroanestezjologii Katedry*  
*Anestezjologii i Intensywnej Terapii GUMed*  
*ul. Smoluchowskiego 17, 80–214 Gdańsk, Poland*  
*e-mail: zkarw@gumed.edu.pl*

*Received: 31.03.2013*

*Accepted: 28.06.2013*