

Case report

Prenatal diagnosis of interrupted aortic arch and oesophageal atresia – monitoring and postnatal management with positive outcome – case report



Łucja H. Biały¹ , Oskar Sylwestrzak¹ , Iwona Maroszyńska² ,
Anna Piaseczna-Piotrowska³ , Piotr Grzelak⁴ , Tomasz Moszura⁵ ,
Katarzyna Januszewska⁶ , Edward Malec⁶ 

¹Department for Prenatal Cardiology, Polish Mother's Memorial Hospital – Research Institute in Lodz, Poland

²Clinic of Intensive Care and Congenital Defects of Newborns and Infants, Polish Mother's Memorial Hospital – Research Institute in Lodz, Poland

³Department of Surgery, Paediatric Urology and Transplantology, Polish Mother's Memorial Hospital – Research Institute in Lodz, Poland

⁴Department of Diagnostic Imaging, Polish Mother's Memorial Hospital – Research Institute in Lodz, Poland

⁵Cardiology Clinic, Polish Mother's Memorial Hospital – Research Institute in Lodz, Poland

⁶Cardiac Surgery Clinic, Polish Mother's Memorial Hospital – Research Institute in Lodz, Poland

Abstract

This paper presents a rare case of a fetus with more than one “lethal” malformation complex heart defect: interrupted aortic arch (IAA) with atrio-ventricular canal, oesophageal atresia, and agenesis corpus callosum. Prenatal diagnosis allowed for transfer in utero, and fetal echocardiography longitudinal monitoring to confirm fetal well-being and to avoid prematurity. Delivery happened in a tertiary centre, and there was an early postnatal surgery: on the 2nd day a successful thoracoscopic repair of the oesophagus was done, and on the ninth day binding of both pulmonary arteries was set up. Despite the poor prognosis at the time of prenatal detection of malformations, our patient was discharged home after a 54-day hospital stay, in good postnatal clinical condition. It is the first case from our unit dealing with congenital malformations presenting a fetus and neonate who required 2 surgeries early after birth (thoracoscopy for oesophageal repair and palliative cardiac surgery – binding of pulmonary arteries) with positive outcome, representing a milestone for prenatal malformations from the perspective of a tertiary centre.

Key words: CHD, interrupted aortic arch, oesophageal atresia.

Corresponding author:

Łucja H. Biały
Department of Prenatal Cardiology
Polish Mother's Memorial Hospital – Research Institute
281/289 Rzgowska St
93-338 Lodz, Poland
e-mail: lucja.bialy@gmail.com

Case study

This was the third pregnancy of a 38-year-old woman with hypothyroidism and gestational diabetes. Two previous pregnancies were delivered by caesarean section, and both resulted in healthy neonates. It was a dichorionic diamniotic twin

pregnancy. The first examination of the fetuses took place at 6 weeks of gestation. At 13 weeks of gestation, NT was measured at 1.9 mm (twin A) and 1.7 mm (twin B), and then, during a routine examination at 24 weeks of gestation, the obstetrician observed abnormal structure of the heart and its vessels in

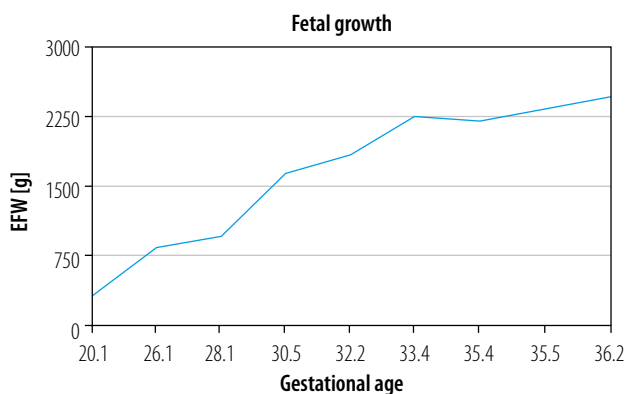


Figure 1. Prenatal fetal growth starting with examination at 20.1 weeks of gestation, with the last one at 36.2 weeks of gestation

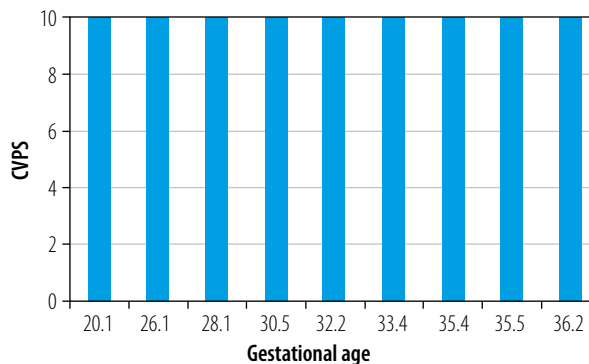


Figure 2. Fetal cardiovascular profile score (CVPS) evolution throughout pregnancy

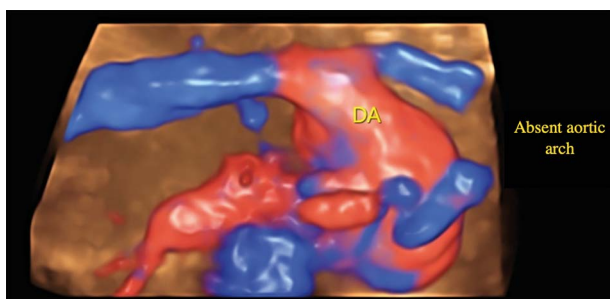


Figure 3. Prenatal image of interrupted aortic arch

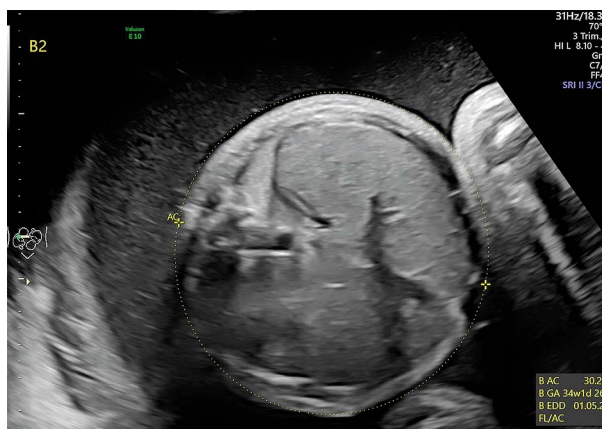


Figure 4. Lack of properly filled stomach

one of the twins (A); the other presented normal heart anatomy (B). During fetal echocardiography, interrupted aortic arch (IAA) with hypoplastic ascending aorta, AVSD, and oesophageal atresia were suspected [1, 2]. Amniocentesis and genetic consultation were ordered, but they showed normal karyotype. Fetal MRI was also done at 28 weeks of gestation, which confirmed the earlier diagnosis of both heart defect and oesophageal atresia [3]. The woman was referred from the south of Poland to Lodz (280 km) for delivery planning.

At the Department of Fetal Cardiology in Lodz US and fetal echocardiography exams were performed at 35.5 and 36.2 weeks of gestation. Neither of the fetuses (A and B) presented any signs of circulatory failure (Figures 1, 2).

Fetal abnormalities were confirmed: the heart area/cardiothoracic area (HA/CA) ratio was lower than average at 0.23 with AP 33 mm. The maximal size of aorta was 4 mm with hypoplastic ascending aorta and aortic arch (Figure 3), and normal sizes of SVC and IVC. Along the course of the aorta, vena azygos could be observed. There was also AV-canal with regurgitation. FO was not obstructed. The diameter of the pulmonary valve was dilated at 15 mm, suggesting the possibility of neonatal pulmonary hypertension. Maximal velocity in PV was 97 cm/s with comb-like flow.

The stomach could not be seen during any of previous fetal ultrasounds (20.1, 26.1, 28.1, 30.5, 32.2, 33.4, and 35.4 weeks of gestation), as well as in the fetal ultrasound done at 35.5 and 36.2 weeks, which indicated probable oesophageal atresia (Figure 4). Other observed abnormalities included partial agenesis corpus callosum and polyhydramnios.

In each fetal exam, the cardio-vascular profile score (CVPS) was 10 (Figure 2).

The Fetal Team discussed the prenatal findings, and elective CS was planned at the beginning of the week, with a full perinatology team on stand-by. The securing of the umbilical vein due to Prostin administration were advised (Figure 5).

At 36.4 weeks of gestation 2 female newborns were delivered via C-section. Twin A was born with an Apgar score of 7/7/9/9 and a birth weight of 2175 g. Right after birth, Prostin infusion was administered to maintain ductal permeability. Twin B's Apgar score was 9/9 with a birth weight of 2190 g. She was discharged home after 14 days.

Neonatal twin A's echocardiographic examination confirmed the prenatal diagnosis of AVSD, hypoplastic aortic valve, interrupted aortic arch (type B) with wide PDA connecting with descending aorta, and normal abdominal aorta.

To confirm oesophageal atresia a gastric tube was inserted. The contrast material revealed dilation of the oesophagus at Th5 (13 mm) with blockage in the following part (Figure 6). On the second day thoracoscopy was done with subsequent oesophagus repair. Three trocars were placed in triangulation: one under the axilla, another at the tip of the scapula for 30° optics (5 mm), and the other one on the antero-axillary line. Capnothorax was established with CO₂ insufflation. After identifying the vagus nerve and azygos vein, the TEF was dissected and isolated and clipped with 2 clips close to the trachea. The proximal oesophagus was elongated by blunt dissection. Once adequate mobilisation was obtained, the tip was cut off. Finally an anastomosis was performed – the 2 ends of the oe-

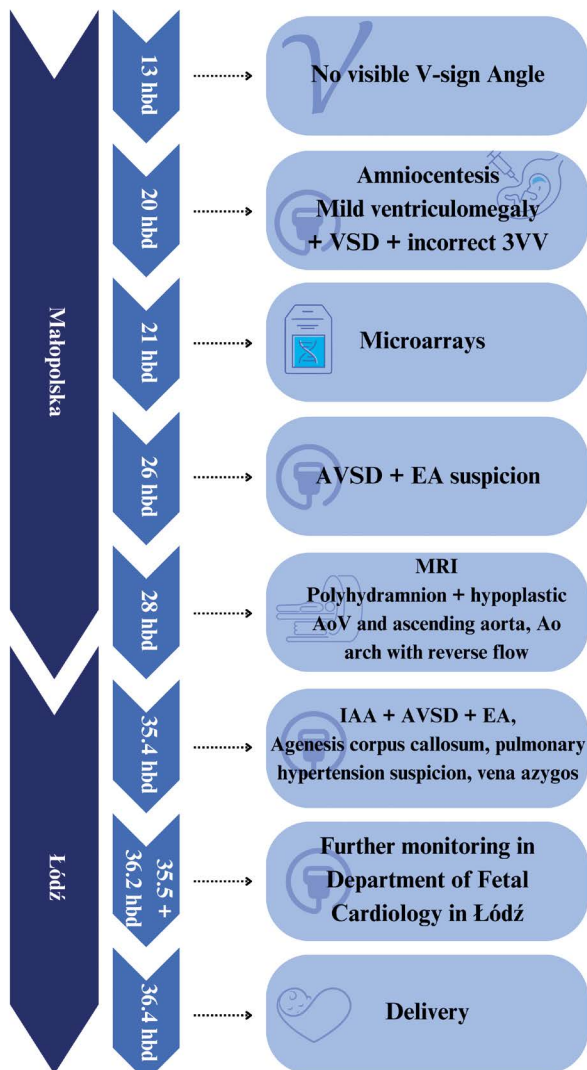


Figure 5. Summary of prenatal care

sophagus were connected. After 6 days an X-ray examination showed no visible postoperative leakage in the oesophagus. In the follow-up pneumothorax ultrasound, lymphorrhoea was determined, which disturbed the pulmonary gas exchange, so a bilateral pleural drainage was placed. During transfontanelle ultrasound asymmetrical rounding of the anterior horns of the lateral ventricle was confirmed.

On the ninth day, binding of both pulmonary arteries was set up. Then on the 48th day a PDA stent was placed to stop Prostin infusions. After surgical consultation the Norwood procedure was deferred.

After 54 days in the hospital ward, she was discharged home.

Discussion

Interrupted aortic arch is a rare CHD, and it is described as complete lack of connection between the ascending and descending aorta [4]. Prenatally the blood flow in the descending aorta is mostly dependent on DA. This is why defects of aortic isthmus region should always indicate a duct-dependent variant of the defect, usually associated with AVSD. Therefore, it

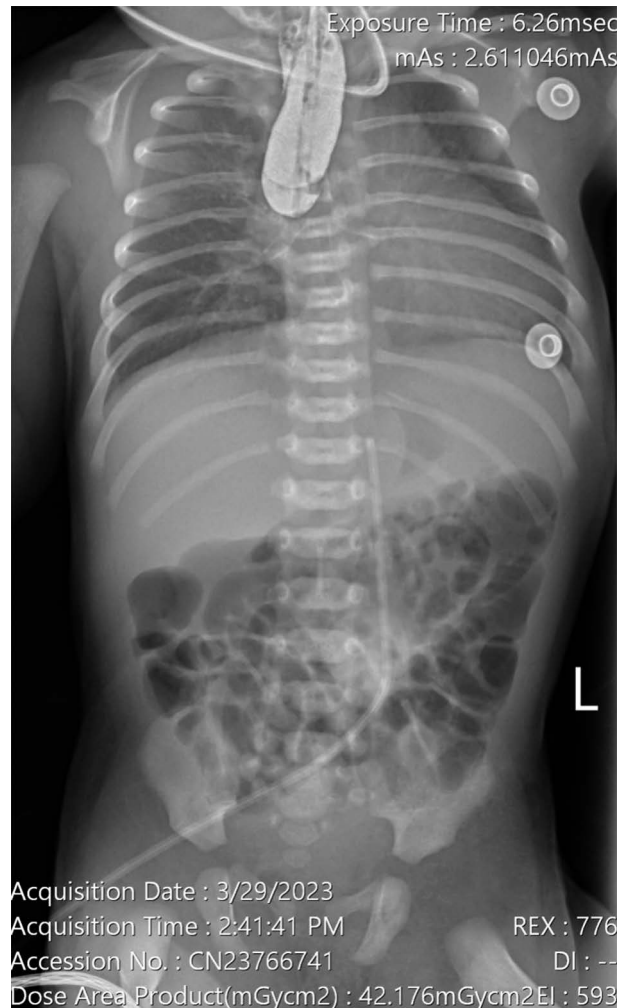


Figure 6. Chest X-ray showing oesophageal atresia in the newborn

is crucial to maintain DA after the delivery by administering Prostin [5].

It is worth mentioning that nowadays most anomalies of the aortic arch are detected during the routine examination of the second trimester, as in this case [2, 6]. However, we should consider that if simple study techniques of the fetal heart, such as 4CV and 3VV colour Doppler, had been used in the first-trimester examination, the anomaly could have been detected earlier on the pregnancy.

In this case, in postnatal echocardiography this defect was confirmed and classified as IAA type B, which means than discontinuity occurred between the left common carotid and left subclavian arteries [7]. In most cases the neonates present shock or severe heart failure in the first 2 weeks of life, but in this case the neonate survived, despite other extracardiac defects such as oesophageal atresia (OA) [8].

Oesophageal atresia is a disorder of the digestive system in which the oesophagus does not develop properly – the upper oesophagus end does not connect with the lower oesophagus and stomach. In most cases a top end of the lower oesophagus connects to the windpipe – a tracheoesophageal fistula (TOF). Some babies with EA-TOF will also have other problems, such as heart or other digestive tract disorders. Although OA can be a life-threatening in its most severe forms and could cause

long-term nutritional problems, most children fully recover. The best treatment for OA is usually surgery to reconnect the two ends of the baby's oesophagus to each other.

There are two main approaches to surgical repair of OA with primary anastomosis: open repair (thoracotomy) and thoracoscopic repair. Thoracoscopic repair of oesophageal atresia was first performed in 2000 and remains one of the most effective treatments currently available. This approach offers multiple advantages (possibility of magnification, better cosmesis, fewer musculoskeletal deformities) but concurrently requires greater operative experience in this field.

Oesophageal atresia is not usually easily detected during ultrasound examination of the fetus. Two ultrasound findings are proved to be correlated with OA, such as small or absent stomach (found in 50.0% of cases [9]) and polyhydramnios, which is present in 56.3% of cases [9]. Pardy *et al.* concluded that to provide an adequate diagnosis, ultrasound examination should be combined with fetal MRI in cases like this [3, 9].

Cases of patients with oesophageal atresia with CHD are usually treated by thoracotomy [10], but in this instance it was possible to treat it with thoracoscopy [11-14].

There are many cases of patients with isolated IAA and OA that have resulted in good postnatal outcome after surgical correction. However, in this case it was not just an isolated case of IAA and OA, but of both combined. And even though the thoracotomy was not done, the patient survived and was later discharged home in good condition. The literature does not contain another case like this.

Both of those combined suggest poor postnatal outcome, especially being dealt with without having laparotomy done, but early and accurate prenatal diagnosis, and later regular ultrasound examinations of the fetus and progression of its malformations, allowed for the best possible outcome.

We would like to especially thank doctors from the University Hospital in Krakow and Lab of Fetal Echocardiography, Medical Centre Ujastek for referring the patient to the Department of Fetal Cardiology in Łódź. Thanks to this cooperation the patient could receive the best care possible.

Conclusions

Early prenatal diagnoses including ultrasound exams, echocardiography for diagnosis and monitoring, fetal MRI, genetic evaluation, and transfer in utero allowed, in a tertiary centre, for the Fetal Team to be prepared for complex and difficult neonatal problems. Early thoracoscopic surgery repair and complex cardio surgery treatment (banding of pulmonary arteries and stenting ductus arteriosus) by the ninth day of postnatal life allowed the rescue of this neonate.

Conflict of interest

The authors declare no conflict of interest.

REFERENCES

1. Słodki M, Moszura T, Janiak K, Sysa A, Seligman NS, Weiner S, et al. The three-vessel view in the fetal mediastinum in the diagnosis of interrupted aortic arch. *Ultrasound Med Biol* 2011; 37: 1808-1813.

2. Wójtowicz A, Huras H. The 1st and 2nd trimester scan of the fetal heart in the case of interrupted aortic arch – case report. *Prenat Cardio* 2014; 4: 20-23.
3. Ethun CG, Fallon SC, Cassady CI, Mehollin-Ray AR, Olutoye OO, Zamora IJ, et al. Fetal MRI improves diagnostic accuracy in patients referred to a fetal center for suspected esophageal atresia. *J Pediatr Surg* 2014; 49: 712-715.
4. Vogel M, Vernon MM, McElhinney DB, Brown DW, Colan SD, Tworetzky W. Fetal diagnosis of interrupted aortic arch. *Am J Cardiol* 2010; 105: 727-734.
5. Jonas RA. Management of interrupted aortic arch. *Semin Thorac Cardiovasc Surg* 2015; 27: 177-188.
6. Augustyniak A, Słodki M, Krajewski W, Moll J, Respondek-Liberska M. Comparison of the clinical status and the effects of treatment of newborns with interrupted aortic arch diagnosed prenatally and postnatally in the “Polish Mother’s Memorial” Institute in Lodz in the years 2003-2012. *Prenat Cardio* 2014; 4: 11-19.
7. Hanneman K, Newman B, Chan F. Congenital variants and anomalies of the aortic arch. *Radiographics* 2017; 37: 32-51.
8. Puri K, Morris SA, Mery CM, Wang Y, Moffett BS, Heinle JS, et al. Characteristics and outcomes of children with ductal-dependent congenital heart disease and esophageal atresia/tracheoesophageal fistula: a multi-institutional analysis. *Surgery* 2018; 163: 847-853.
9. Pardy C, D’Antonio F, Khalil A, Giuliani S. Prenatal detection of esophageal atresia: a systematic review and meta-analysis. *Acta Obstet Gynecol Scand* 2019; 98: 689-699.
10. Fernandes E, Kusel A, Evans S, Houghton J, Hamill JK. Is thoracoscopic esophageal atresia repair safe in the presence of cardiac anomalies? *J Pediatr Surg* 2020; 55: 1511-1515.
11. Ishimaru T, Fujiogi M, Michihata N, Matsui H, Fushimi K, Kawashima H, et al. Impact of congenital heart disease on outcomes after primary repair of esophageal atresia: a retrospective observational study using a nationwide database in Japan. *Pediatr Surg Int* 2019; 35: 1077-1083.
12. Encinas JL, Luis AL, Avila LF, Martinez L, Guereta L, Lassaletta L, et al. Impact of preoperative diagnosis of congenital heart disease on the treatment of esophageal atresia. *Pediatr Surg Int* 2006; 22: 150-153.
13. Puliński M, Chojiński W, Stega M. Congenital esophageal atresia treated with thoracoscopic approach – results of surgical treatment. *Pol Ann Med* 2020; 27: 89-95.
14. Galazka P, Skinder D, Styczynski J. Short-term and mid-term effects of thoracoscopic repair of esophageal atresia: no anastomotic leaks or conversions to open technique. *Front Surg* 2022; 9: 1009448.

Division of work:

Łucja H. Biały (ORCID: 0009-0004-5571-8535): collection and/or assembly of data, writing the article.

Oskar Sylwestrzak (ORCID: 0000-0001-9325-7304): data analysis and interpretation.

Iwona Maroszyńska (ORCID: 0000-0003-4061-4843): final approval of the article.

Anna Piaseczna-Piotrowska (ORCID: 0000-0002-2692-8339): final approval of the article.

Piotr Grzelak (ORCID: 0000-0002-0970-2717): final approval of the article.

Tomasz Moszura (ORCID: 0000-0003-3876-2791): final approval of the article.

Katarzyna Januszewska (ORCID: 0000-0001-5031-150X): final approval of the article.

Edward Malec (ORCID: 0009-0003-3770-7034): final approval of the article.